

Pleural Disease in Lymphangiomyomatosis

Khalid F. Almoosa, MD^{a,*}, Francis X. McCormack, MD^a,
Steven A. Sahn, MD^b

^a*Department of Internal Medicine, Division of Pulmonary, Critical Care, and Sleep Medicine, University of Cincinnati College of Medicine, 231 Albert Sabin Way, 6004 MSB, PO Box 670564, Cincinnati, OH 45267-0564, USA*

^b*Division of Pulmonary and Critical Care Medicine, Department of Allergy and Clinical Immunology, Medical University of South Carolina, Charleston, SC, USA*

Lymphangiomyomatosis (LAM) is a rare lung disease of unknown etiology that is characterized by the proliferation and infiltration of the pulmonary interstitium with atypical smooth muscle cells [1–3]. The first case description was published in 1919 in a child with tuberous sclerosis complex (TSC) who presented with bilateral spontaneous pneumothorax [4]. TSC is an inherited neurocutaneous disorder with variable penetrance characterized by the development of multiorgan hamartomas, cognitive impairment, and seizures [5–9]. In 1966, Cornog and Enterline [10] attempted to bring order to the LAM literature by clarifying the nomenclature and describing characteristic histologic features in a group of patients. Whether LAM is associated with TSC or not, it occurs almost exclusively in women of reproductive age and leads to the development of numerous pulmonary parenchymal cysts (Figs. 1 and 2). The pathologic findings of TSC-LAM are similar to those found in sporadic LAM and include profuse smooth muscle infiltration of all lung structures—airways, blood vessels, lymphatics, and interstitium [7,9]. In either TSC-LAM or sporadic LAM, progressive respiratory insufficiency and pleural complications, specifically pneumothorax and chylothorax, are the clinical hallmarks. Because most of the initial episodes of pneumothorax or chylothorax occur before the diagnosis of LAM is established, their occurrence is often the

sentinel event that leads the clinician to consider the diagnosis of LAM. Because pleural complications are important for the recognition of LAM and constitute unique challenges for clinical management, this article presents an overview of pleural complications in LAM. There is a paucity of data on this topic, and most of this article is based on published case series and survey reports.

Pneumothorax

Pneumothorax is defined as the abnormal presence of air in the pleural cavity. Pneumothorax can occur traumatically by the introduction of ambient air after penetration of the chest wall and pleura or spontaneously. Spontaneous pneumothorax can occur in patients without clinically apparent underlying lung disease (primary spontaneous pneumothorax) or in patients with pulmonary disorders (secondary spontaneous pneumothorax). Secondary spontaneous pneumothorax can occur with virtually any pulmonary disease, but is more common in specific obstructive, interstitial, and infectious lung diseases, such as chronic obstructive pulmonary disease, cystic fibrosis, Langerhans' cell histiocytosis, and *Pneumocystis jiroveci* pneumonia [11–16].

Incidence, recurrence, and clinical presentation

The incidence of pneumothorax in LAM is one of the highest among diseases associated with secondary

* Corresponding author.

E-mail address: khalid.almoosa@uc.edu (K.F. Almoosa).

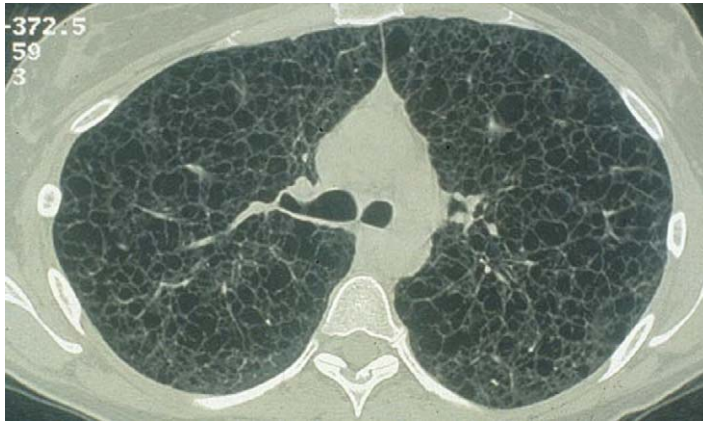

Fig. 1. Chest CT scan of a patient with LAM shows characteristic bilateral cysts of various sizes.

spontaneous pneumothorax (range 39–76%) (Table 1). Pneumothorax frequently is the presenting event that leads to the diagnosis of LAM in affected patients [17–19]. Chu et al [17] reported that pneumothorax was the presenting event leading to the diagnosis of LAM in 15 (63%) of 24 patients with a pneumothorax. Corrin et al [18] reported that 6 (21%) of 28 patients had pneumothorax as a presenting manifestation of LAM. Oh et al [19] reported that 10 (48%) of 21 patients they evaluated had a pneumothorax at presentation; 7 of these 10 patients had recurrent pneumothoraces before the diagnosis of LAM was established. Rarely, bilateral spontaneous pneumothoraces have been reported to be the presenting feature of LAM [20,21]. In a large retrospective study of pneumothorax using the database of the LAM Foundation, Almoosa et al [21] reported that the prevalence of pneumothorax among 395 LAM patients during the course of their disease

was 66% (260 patients). Of the 193 patients who responded to a secondary questionnaire specifically inquiring into the details of their pneumothoraces, most (80%) had developed at least one pneumothorax before their diagnosis of LAM was established (Fig. 3). These patients averaged 2.6 pneumothoraces before diagnosis.

One of the most remarkable characteristics of pneumothorax in LAM is the rate of recurrence (Table 1). Most case series report that most LAM patients developed a recurrent pneumothorax [22–24]. Urban et al [24] reported a recurrence rate of 68% among 69 patients, whereas Taylor et al [23] reported a recurrence in 81% of 32 patients. Not all studies discriminated between ipsilateral and contralateral recurrence, however. In the LAM Foundation study [21], recurrence occurred in 140 (73%) of 193 patients who developed at least one pneumothorax. These recurrences were ipsilateral (71%) and contralateral

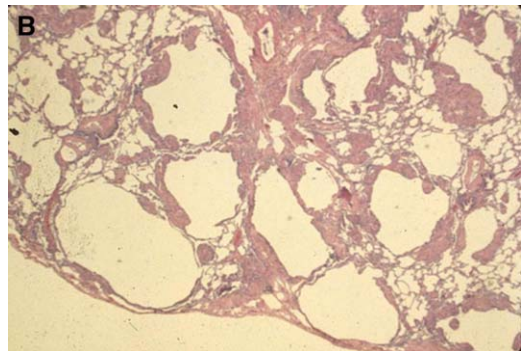
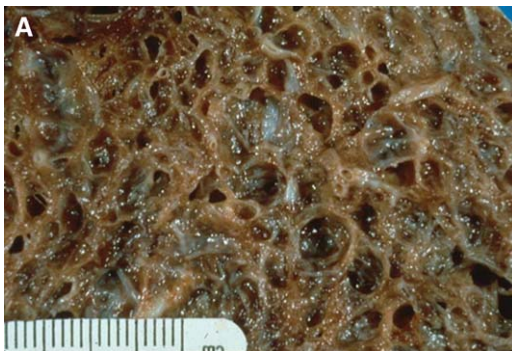

Fig. 2. Gross (A) (From McCormack FX, Sullivan EJ. Lymphangioleiomyomatosis. In: Mason RJ, Murray JF, Courtney V, et al, editors. Murray and Nadel's textbook of respiratory medicine. Fourth Edition. Philadelphia: Harcourt Health Sciences Group; 2005. p. 1706; with permission.) and microscopic (B) appearance of LAM lungs. Multiple cysts throughout both lungs are characteristic of LAM.

Table 1
Prevalence, recurrence rate, and pleurodesis for Pneumothorax during course of lymphangioleiomyomatosis

Author [reference]	No. patients	Incidence of PTX (%)	Recurrence of PTX (%)	No. patients who had pleurodesis (%)
Corrin et al [18]	28	12 (43)	n/a	NA
Taylor et al [23]	32	17 (53)	26 (81)	NA
Kitaichi et al [37]	46	18 (39)	NA	NA
Chu et al [17]	35	24 (69)	NA	19 (54)
Oh et al [19]	21	13 (76)	NA	7 (33)
Urban et al [24]	69	32 (46)	47 (68)	40 (58)
Johnson and Tattersfield [22]	50	30 (60)	23 (46)	NA
Ryu et al [67]	230	128 (56)	NA	NA
Almoosa et al [21]	193	NA	140 (73)	154

Abbreviations: NA, not available; PTX, pneumothorax.

(74%), occurring an average of 21.7 and 30 months after the initial pneumothorax, respectively. Compared with the incidence of recurrence of pneumothorax in other diseases, LAM has the highest rate (Table 2), although the absolute number of pneumothoraces in this patient group is small because of the rarity of the disease. Consistent with the conclusions of the Delphi consensus conference on pneumothorax management, early aggressive intervention is suggested to avoid the morbidity and risk of subsequent pneumothoraces in patients with compromised lung function, although firm evidence to support this approach is lacking [25].

An important alternative diagnosis that must be considered for recurrent pneumothorax in nonsmoking women of childbearing age is catamenial pneumothorax, a spontaneous pneumothorax that occurs during or within 24 to 48 hours of menstruation and is usually, but not always, associated with thoracic

endometriosis [26–28]. A high-resolution CT scan that reveals normal lung parenchyma suggests catamenial pneumothorax, whereas the presence of cysts suggests LAM.

The most common presenting symptoms of pneumothorax are dyspnea and chest pain. In the LAM Foundation study [21], most pneumothorax occurred at rest or with minimal activity (81%). Less commonly, pneumothorax occurred during exertion, such as lifting or during exercise. Four patients developed a pneumothorax during pulmonary function testing, where most described feeling a “pop” in the chest. Cough and hemoptysis also may occur in association with pneumothorax in a few cases.

Bilateral simultaneous pneumothorax is an acute and potentially fatal situation that occurs rarely in patients with underlying lung disease. A few case series have described bilateral simultaneous pneumothorax, and most have occurred in patients with

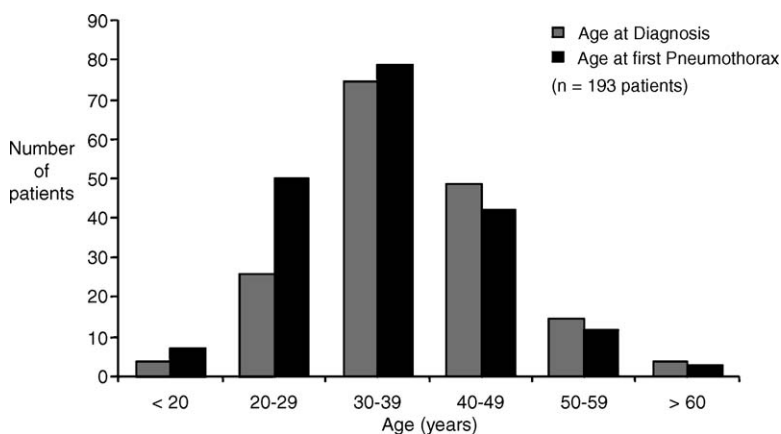


Fig. 3. Age at onset of initial pneumothorax compared with diagnosis of LAM. Most women developed their first pneumothorax before a diagnosis of LAM was established. (From Almoosa KF, Ryu JH, Mendez J, et al. Management of pneumothorax in lymphangioleiomyomatosis: effects on recurrence and lung transplantation complications. Chest 2006;129:1277; with permission.)

Table 2
Prevalence and recurrence rates of secondary spontaneous pneumothorax

	Prevalence	Recurrence
PSP	4.3–12/100,000	16–52%
CF (>18 years old)	16–20%	50–78%
LCH	10–28%	25–50%
COPD	26/100,000	39–47%
LAM	64–66%	62–76%

Abbreviations: CF, cystic fibrosis; COPD, chronic obstructive pulmonary disease; LCH, Langerhan’s cell histiocytosis; PSP, *Pneumocystis jiroveci* pneumonia.

chronic obstructive pulmonary disease, pulmonary or pleural metastases, Hodgkin’s disease, tuberculosis, Langerhans’ cell histiocytosis, undefined interstitial lung disease, cystic fibrosis, and LAM [29–31]. Despite the rarity of LAM, it is routinely mentioned in case reports discussing bilateral simultaneous pneumothorax [20,29]. The LAM Foundation study identified 8 (4%) of 193 patients who developed bilateral simultaneous pneumothorax during the course of their disease, with several patients experiencing recurrent bilateral simultaneous pneumothorax [21].

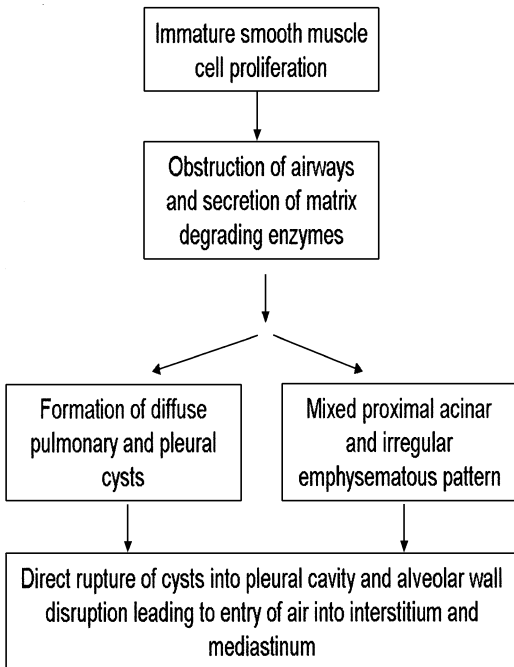


Fig. 4. Pathogenesis of pneumothorax in LAM.

Pathophysiology

The cardinal pathologic feature of LAM is the proliferation of immature smooth muscle cells along the peribronchial, perivascular, and perilymphatic structures [18,32,33]. Compression and obstruction of these conduits result in the development of airflow obstruction and pneumothorax, hemoptysis and alveolar hemorrhage, and chyloptysis and chylothorax, respectively. There is little or no associated inflammation or fibrosis in LAM. Although it is known that smooth muscle cells can infiltrate the pleura, a systematic pathologic study of pleural involvement in LAM has not been reported [34].

Some investigators have suggested that bronchial obstruction by overgrowth of LAM cells is responsible for the obstructive pattern and air trapping (Fig. 4) [2,18,32,33]. It has been postulated that this process ultimately leads to the formation of diffuse, bilateral, thin-walled pulmonary cysts, ranging in size from a few millimeters to a few centimeters in diameter, which are the pathologic and radiographic hallmark of LAM [18,33]. Biopsy specimens also have revealed the presence of a mixed proximal acinar and irregular emphysematous pattern, however, which may be present in areas associated with less affected bronchioles. This finding has led to other theories for the pathogenesis of airflow obstruction, such as the

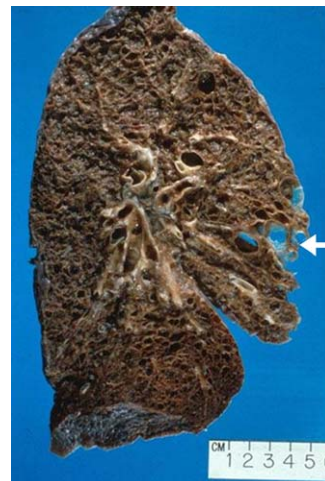

Fig. 5. Lung of LAM patient showing multiple cysts, some of which about the pleura (arrow). (From Almoosa KF, Ryu JH, Mendez J, et al. Management of pneumothorax in lymphangioliomyomatosis: effects on recurrence and lung transplantation complications. Chest 2006;129:1277; with permission.)

destruction of supportive fibers by matrix degrading enzymes resulting in an emphysematous pattern and cyst formation [35,36]. Notwithstanding their origin, these cysts often involve the pleural surface (Fig. 5), and a pneumothorax can occur from their direct rupture into the pleural space or through alveolar wall disruption that allows air to enter the lung interstitium and mediastinum and eventually cause rupture of the mediastinal pleura (Fig. 6).

Radiologic features

The patient's history first suggests the diagnosis of pneumothorax in LAM, and the diagnosis most commonly is confirmed by a standard chest radiograph [17,19,37] showing the classic visceral pleural line that runs parallel to the inner thoracic wall [14]. In some cases, the cystic changes in LAM are apparent on a chest radiograph only when partial collapse secondary to pneumothorax enhances the contrast

between lung tissue and airspace. CT more clearly defines the pneumothorax and may show the classic findings of LAM pathology in the unaffected lung [17,24,37]. These findings include reticulonodular shadows, cysts or bullae, and hyperinflation. Incidental small pneumothoraces occasionally are discovered on CT scans performed for other purposes (see Fig. 6B). Pleurodesis complicates the diagnosis and management of pneumothorax in LAM patients. Patients may present with persistent chest pain, shortness of breath, or subcutaneous emphysema in the absence of a radiographically apparent pneumothorax on chest radiograph. CT may show a small loculated pneumothorax in these instances.

Treatment

All LAM patients should be counseled on the symptoms associated with pneumothorax and given explicit instructions to seek medical care when a

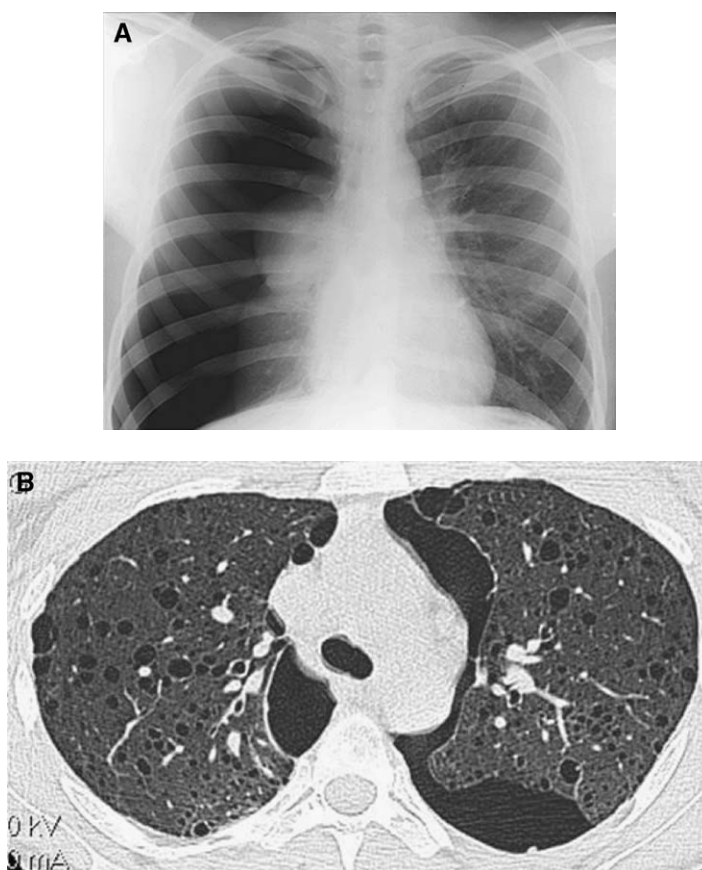


Fig. 6. Chest radiograph (A) and CT scan (B) show pneumothorax in two patients with LAM. The pneumothorax on chest CT scan was discovered incidentally.

pneumothorax is suspected. The American College of Chest Physicians Delphi Consensus Statement published in 2001 offers recommendations on the optimal approach to the management of spontaneous pneumothorax [23,25]. It states that for small or large secondary spontaneous pneumothoraces, whether stable or unstable, chest tube thoracostomy and hospitalization are recommended. For recurrence prevention, most members of the panel suggested a pleurodesis intervention because of the potential lethality of recurrent pneumothoraces in patients with compromised lung function. The preferred intervention for the lung diseases studied in that report was surgical because it was associated with a lower recurrence rate compared with the instillation of a sclerosant [38]. The authors evaluated failure rates for chemical and surgical pleurodesis in LAM [21].

Nonsurgical treatment options for pneumothorax can be divided into lung expansion therapy (ie, conservative, including observation, simple aspiration, and tube thoracostomy) and interventional therapy (ie, chemical pleurodesis). Surgical options include mechanical pleurodesis, talc poudrage at thoracoscopy and thoracotomy, and partial or complete pleurectomy. For secondary spontaneous pneumothorax in general, surgical interventions have been associated with lower recurrence rates than nonsurgical techniques [39,40]. Limited data address this issue in LAM. Only two studies reported success rates of different interventions for pneumothorax. The LAM Foundation study [21] reported lower failure rates with chemical pleurodesis (27%) and surgery (32%) compared with conservative interventions (66%). Johnson and Tattersfield [22] reported that approximately half (23 of 47, 49%) of the patients treated had a recurrence, with most occurring in

patients treated conservatively (20 of 30, 66%) compared with the surgical intervention group (3 of 17, 18%). Although the reason for the poor treatment response for LAM compared with other lung diseases is unclear, it is possible that the dramatic profusion of blebs on the lung surface could limit the apposition of the visceral and parietal pleurae after mechanical abrasion or chemical sclerosant instillation and lead to incomplete fusion.

One of the major conclusions of the LAM Foundation study was that current experience with pneumothorax in LAM supports an early interventional procedure—chemical pleurodesis or surgery—after the first pneumothorax. This recommendation was made because of the high incidence of pneumothorax recurrence and associated morbidity, including a lifelong average of 1 month in the hospital for pneumothorax management in LAM patients who develop an initial pneumothorax (Fig. 7). Most initial pneumothoraces in LAM patients occur before the diagnosis of LAM, however [21,22,24,37]. Patients often experience several pneumothoraces before a diagnosis is established and an intervention is performed. The paucity of data and published literature on this issue is a major impediment to the development of recommendations with a high degree of clinical confidence.

Patient perspectives on interventions for pneumothorax in LAM also have been addressed. In a study by Young et al [41], 314 patients registered with the LAM Foundation were given a questionnaire inquiring into their perspectives regarding different treatment options. Although 41% believed that a previous pneumothorax contributed to the decline in their lung function, and one third made lifestyle modifications to prevent pneumothorax, only 12% worried about

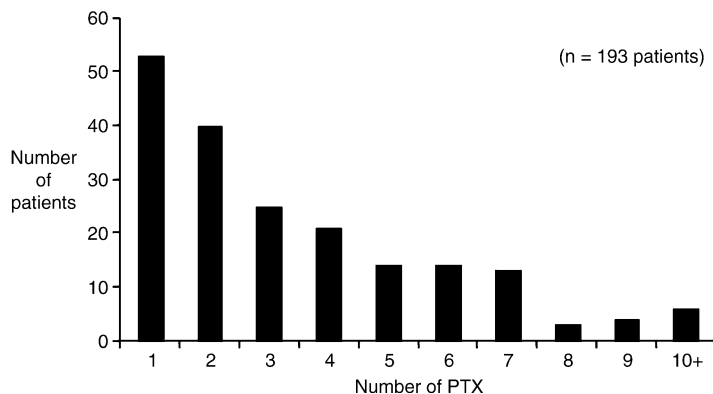


Fig. 7. Recurrence of pneumothorax (PTX) in LAM. Most LAM patients developed multiple pneumothoraces during their lifetime. (From Sullivan EJ. Lymphangiomyomatosis: a review. *Chest* 1998;114:1689–703; with permission.)

developing a pneumothorax. Although most patients agreed that pleurodesis helps prevent pneumothorax recurrence, only 25% thought it was appropriate for the first pneumothorax, and only 60% believed it was appropriate for a recurrence. This finding may be related to concerns of extensive and inadequately treated pain associated with chest tube thoracostomy that were reported by the subjects. This study suggests that views between physicians and patients differ regarding the optimal therapy for pneumothorax in LAM, and that patients favor a more conservative approach initially. It remains to be determined whether optimal pain management may change these views.

Effect of treatment on lung transplantation

Interventional approaches for pneumothorax in LAM may affect candidacy and outcomes of lung transplantation. As obstructive lung disease progresses in this population of young, otherwise healthy women, lung transplantation frequently is considered. It is well accepted that prior chemical or surgical pleurodesis increases the risk of perioperative bleeding in any lung transplant recipient [42,43]. LAM patients are prone to pleural complications and often present for consideration for lung transplantation after unilateral or bilateral pleurodesis. It is especially important to understand the consequences of pleural interventions in LAM patients to minimize the impact of pleural management decisions on eligibility for lung transplantation.

Few studies have evaluated specifically the outcomes of lung transplantation in LAM patients who have had a pleural symphysis procedure (Table 3). Boehler et al [44] conducted a retrospective survey of 34 LAM patients who underwent lung transplantation at 16 centers in the United States and Europe. Of patients, 27 received single-lung transplants, 6 received bilateral transplants, and 1 received a heart-lung transplant. Of 34 patients, 13 (38%) had previous pleurectomy or pleurodesis. Also, 18 (53%) of 34 patients had extensive pleural adhesions, which

were judged to be of moderate severity in 8 and severe in 10 cases. In addition, 13 (72%) of 18 cases of pleural adhesions were believed to be secondary to the underlying disease because they occurred in patients who had not had previous pleural interventions, whereas the remaining 5 (28%) were due to prior pleurectomy. Moderate-to-severe hemorrhage occurred in four patients, leading to intraoperative death in one patient and repeat thoracotomy in two patients. Overall, post-transplantation survival in this cohort of LAM patients was similar to other chronic lung disease populations. The authors concluded that although perioperative complications do occur in LAM patients who had pleural procedures, lung transplantation remains an important option that improves long-term outcomes.

A study by Pechet et al [45] retrospectively evaluated seven single and seven bilateral lung transplant recipients for LAM. All 14 patients had multiple previous pleurodeses for pleural complications of LAM, and 6 patients had at least one thoracotomy for pleurectomy or bullectomy. Extensive pleural adhesions were present in 10 (71%) of 14 patients, and 7 (50%) experienced blood loss greater than 1000 mL intraoperatively. There were no perioperative deaths. The authors concluded that although perioperative morbidity is common in LAM patients undergoing lung transplantation, early and late survival is comparable to that of lung transplant patients for other diseases.

In the LAM Foundation study [21], 85 registered LAM Foundation patients who received a lung transplant were sent a questionnaire focused on the impact of pleural symphysis on complications arising in the perioperative period. Data from 80 recipients of 81 transplants (1 patient had a re-transplant) were evaluated. In 45 (56%) of 80 patients, chemical or surgical pleurodesis had been performed before the transplant for a pneumothorax or a chylothorax. In 12 (27%) of 45 patients, the side of previous pleural procedure influenced the side of the lung transplant. Fourteen (18%) of 80 patients reported pleural-related bleeding complications perioperatively, 13 (93%) of

Table 3
Lung transplantation, pleurodesis, and perioperative bleeding in lymphangioleiomyomatosis

Author [reference]	No. patients transplanted	No. patients with previous pleurodesis (%)	No. patients with adhesions seen during surgery	No. patients with perioperative bleeding
Pechet et al [45]	14 (7 single, 7 bilateral)	14 (100)	10	7
Boehler et al [44]	34 (27 single, 6 bilateral, 1 heart-lung)	13 (38)	18	4
Almoosa et al [21]	81 (38 single, 43 bilateral)	45 (56)	NA	14

Abbreviation: NA, not available.

whom had previous pleural procedures. Half (7 of 14) of these complications required a return to surgery, and most occurred in patients with previous bilateral pleural procedures. The average length of stay in the group with prior pleural procedures tended to be greater than the group without prior procedures (33.5 ± 5.4 days versus 26.4 ± 6.2 days), although the difference was not statistically significant. There were no perioperative deaths. These results indicate that although perioperative complications, bleeding in particular, are common in patients with prior pleural interventions, they are generally manageable.

An ongoing study is evaluating the bias of transplant centers regarding candidacy for transplant in LAM patients who have had previous pleurodesis (Chris Lyons, personal communication, 2005). Of 52 centers evaluated, 22 responded, of which 40% considered previous bilateral pleurodesis with talc or pleurectomy a contraindication to transplant. Paradoxically, most centers (55%) agreed that talc was the preferred agent for pleurodesis for pneumothorax recurrence. In the LAM Foundation study, 43% of patients had bilateral pleurodesis before transplant [21]. This study suggests considerable controversy exists regarding the optimal management for pleural disease in LAM.

Specific situations of pneumothorax in lymphangiomyomatosis

The risk of developing a pneumothorax in LAM patients may be increased further during certain activities or specific situations. Air travel poses a potential risk for patients with underlying lung disease. The decrease in partial pressure of oxygen that accompanies the fall in cabin pressure during commercial flights results in several physiologic responses, including hyperventilation, pulmonary vasoconstriction, and an altered ventilation-perfusion ratio, which may place increased demand on the respiratory system [46,47]. Patients with chronic obstructive pulmonary disease may experience hypoxemia during air travel [47,48], and pneumothorax during flight has been reported in patients with underlying lung disease [49–52]. There are no data, however, on the incidence or risk of pneumothorax in LAM patients during flight. Data collected through the LAM Foundation on the incidence of pneumothorax during commercial flight reported a total of 8 (2%) cases of pneumothorax among 395 registered patients (Eugene Sullivan, MD, personal communication, 2005). Without knowing the number of flights, the distances traveled, or the altitudes reached during all trips taken by these patients, no firm conclusions regarding the

risk of flight on the development of pneumothorax in LAM can be reached.

Pregnancy may contribute to an increased risk of pleural complications in LAM. Several investigators have speculated that the elevated hormonal levels associated with pregnancy may accelerate the progression of LAM. The changes in lung volumes and pressures that occur with pregnancy may increase the risk of pleural complications. No published reports specifically describe the prevalence of pneumothorax in pregnant LAM patients. A few subjects reported in two separate LAM cases series developed a pneumothorax during pregnancy, however. Johnson and Tattersfield [22] reported that 7 (14%) of 50 LAM patients studied were pregnant, 3 (43%) of whom developed a pneumothorax during pregnancy. In the 21 patients evaluated by Oh et al [19], all 3 patients who were pregnant developed a pneumothorax during pregnancy. In view of this paucity of data, the LAM Foundation conducted a survey among registered patients inquiring into the incidence and management of pneumothorax during pregnancy (Janet Maurer, MD, MBA, personal communication, 2005). Of the 239 registered women who had at least one pregnancy, 53 (22%) reported complications associated with their pregnancy and received a second questionnaire. Among the 41 respondents, there were a total of 80 pregnancies. Twenty-one patients had a total of 122 pneumothoraces that complicated 49 pregnancies. Of these patients, 16 (76%) experienced their initial pneumothorax during pregnancy, and in 7 it led to the diagnosis of LAM. Ten (48%) of 21 patients eventually required surgical management of pneumothorax, and 13 (62%) pregnancies were delivered by cesarean section because of pneumothorax. Twenty (95%) patients reported that the occurrence of pneumothorax discouraged them from future pregnancies, and 30 (73%) of 41 believed that pregnancy accelerated their pulmonary deterioration. These data suggest that pneumothorax is common in pregnant LAM patients and may influence the mode of delivery and decisions about future pregnancies. In addition, most patients thought that pregnancy accelerated the deterioration of their pulmonary function.

Chylothorax

Chylothorax is defined as the accumulation of chyle in the pleural space [53]. It results from disruption or obstruction of the thoracic duct or its tributaries in the thorax by tumor, trauma, or surgery, leading to leakage of chyle into the thoracic cavity

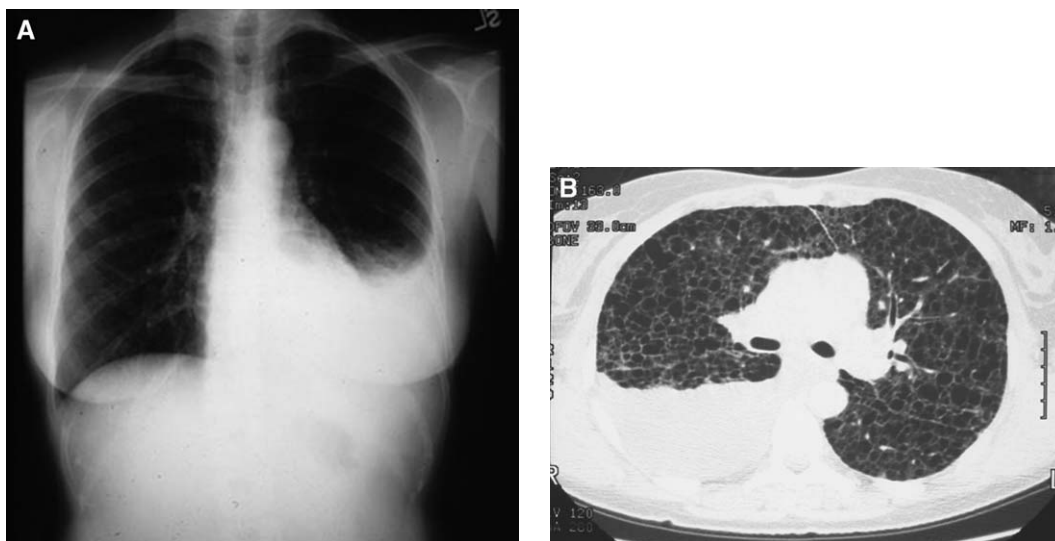


Fig. 8. Chest radiograph (A) and CT scan (B) (From McCormack FX, Sullivan EJ. Lymphangiomyomatosis. In: Mason RJ, Murray JF, Courtney V, et al, editors. Murray and Nadel’s textbook of respiratory medicine. Fourth Edition. Philadelphia: Harcourt Health Sciences Group; 2005. p. 1708; with permission.) shows chylothoraces in two LAM patients.

[53,54]. Chylothorax also may complicate medical disorders, such as superior vena cava syndrome, lymphatic disorders such as lymphangiomatosis, and yellow nail syndrome [53,55–57]. Chylothorax is a well-recognized complication of LAM (Fig. 8) [17–19,22–24,37,58–67].

Prevalence and clinical presentation

Table 4 summarizes the prevalence of chylothorax in LAM patients based on published reports. Chylothorax is a less common pleural complication of LAM than pneumothorax, with a prevalence of about 20% to 30% among all reported cases. Most

chylothoraces are unilateral with no side preference, and most are large enough to require intervention [58,64,65,68–70]. Reports often describe the occurrence of a pneumothorax or a chylothorax complicating LAM, but these two complications rarely seem to occur simultaneously. Abdominal involvement in patients with chylothorax also may be present, manifesting as chylous ascites and lymphadenopathy [66,71–73]. The clinical presentation of chylothorax almost invariably includes progressive dyspnea, but this may be a manifestation of the underlying lung disease and the pleural effusion. Chest pain, cough, and chyloptysis also may occur. In a retrospective review of 79 LAM patients, Ryu et al [69] identified 8 (10%) who developed a chylothorax. The average age at presentation of chylothorax in these LAM patients was 41.1 years compared with the average age for diagnosis of LAM of 34 years. The occurrence of chylothorax in these patients did not correlate with the extent of lung involvement.

Pathophysiology and diagnosis

Chylothorax in LAM most likely results from obstruction of lymphatic vessels by infiltration of smooth muscle cells. Lymphangiography has shown that obstruction occurs at several different levels, causing chyle leakage to occur on the surface of the lung, pleura, and mediastinum [18,70,74]. A histologic section of the thoracic duct in a LAM patient typically reveals a grossly enlarged duct containing

Table 4
Prevalence of chylothorax during course of lymphangiomyomatosis

Author [reference]	No. patients	Prevalence of chylothorax (%)
Corrin et al [18]	28	11 (39)
Taylor et al [23]	32	9 (28)
Kitaichi et al [37]	46	3 (7)
Chu et al [17]	35	8 (23)
Oh et al [19]	21	0
Urban et al [24]	69	20 (29)
Johnson and Tattersfield [22]	50	11 (22)
Ryu et al [69]	79	8 (10)
Ryu et al [67]	230	48 (21)
Total	590	118 (20)

proliferating smooth muscle cells [75]. Evidence suggests that lymphangiogenesis plays a role in disease progression. Kumasaka et al [76] used immunohistochemistry to identify VEGFR-3, a vascular endothelial growth factor (VEGF) receptor and specific marker for lymphatic endothelial cells, and VEGF-C, a lymphatic-specific VEGF, in specimens obtained from autopsy and surgical cases. They concluded that lymphatics were extremely abundant in pulmonary and extrapulmonary LAM, and lymphangiogenesis was abundant in vascular walls and interstitium surrounding the area where LAM cells were proliferating. In addition, a significant correlation was noted between the degree of lymphangiogenesis in LAM or VEGF-C expression on LAM cells and the LAM histologic score, which represents the histologic severity of pulmonary LAM, a prognostic indicator. Chylothorax also may develop through transdiaphragmatic flow of chylous ascites. Thoracic and abdominal lymphadenopathy may be present [17] and reveal proliferating smooth muscle cells [75]. Globular collections of HMB 45–positive cells can be found in the pleural fluid [77,78]. In a subsequent study, Kumasaka et al [79] further showed that these clusters of LAM cells are enveloped by VEGF-positive lymphatic endothelial cells, and that the shedding of these structures into the lymphatic circulation may play a central role in the dissemination of LAM lesions.

The diagnosis of chylothorax should be entertained when a LAM patient presents with a pleural effusion on a chest radiograph. Although most pleural effusions in LAM are chylothoraces [2,17,70,80], diagnostic thoracentesis should be performed to confirm the diagnosis. A triglyceride level greater than 110 mg/dL makes the diagnosis highly likely, and the presence of chylomicrons on lipoprotein electrophoresis is confirmatory if the triglyceride concentration is less than 110 mg/dL. Radionuclide or contrast lymphangiography may be used to locate the site of thoracic duct obstruction [81,82].

Treatment

Management of chylothorax in LAM is no different than for other diseases [53,54,83]. Although the treatment of the underlying cause may help in treating chylothorax in other diseases, it is problematic in LAM because there is no effective therapy for LAM. Management is based on clinical experience and anecdotal reports. Nonoperative management, consisting of aspiration or thoracostomy tube drainage, often is done initially to re-expand the lung and improve symptoms. Because there is a high risk of nutritional

depletion with persistent drainage, careful monitoring of the patient's weight, serum prealbumin and albumin, total protein, absolute lymphocyte count, and electrolyte levels is essential [54,84]. The nutritional approach to chylothorax involves substitution of long-chain dietary fat with medium-chain triglycerides, which do not become incorporated into chylomicrons. Dietary supplements can be oral or intravenous. Hyperalimentation with medium-chain triglyceride supplementation can shorten the duration of the chylous effusion [22,70,85], although variable degrees of success have been reported in adults [86]. Similarly, total parenteral nutrition has been used to replete nutrients and decrease chyle formation in persistently draining effusions and is generally more effective than dietary modification [87]. Improvements in the formulation and delivery of total parenteral nutrition have improved the safety and reliability of this mode of supplementation, although it remains costly [88].

Nonoperative drainage may be useful initially to improve symptoms, but many patients eventually require a chemical or surgical pleurodesis procedure [22,69]. This intervention seems to be more successful at preventing recurrences of chylothorax than drainage alone [10,70,89–91]. In the series by Ryu et al [69], four of five patients with recurrent chylothorax were treated successfully with pleurodesis. Thoracic duct ligation [10,70,92,93] and the placement of a LeVeen shunt [24] have been attempted, with variable success.

Hormonal therapy has been used to treat LAM lung disease with mixed results [94–97]. Some studies have reported that medroxyprogesterone therapy has been useful in treating chylothorax that complicates LAM [23,37,69]. Taylor et al [23] found that most patients whose LAM improved with medroxyprogesterone therapy had chylothorax or chylous ascites present. The authors postulated that the presence of chylothorax seemed to be a marker for clinical response and might reflect a reversible element in the LAM-affected lung. Octreotide, a long-acting somatostatin analogue, also has been reported to be effective in treating persistent chylothorax in several case reports [98–102]. Octreotide reduces the thoracic duct flow and triglyceride levels and may be particularly effective when combined with a reduction in oral intake.

Summary

LAM is a rare, gender-restricted interstitial lung disease that causes significant morbidity and mortal-

ity. Pneumothorax or chylothorax occurs during the course of illness in most patients. The incidence of secondary spontaneous pneumothorax in LAM is among the highest of all chronic lung diseases and may result in considerable morbidity. The effect of pneumothorax and chylothorax on disease progression and prognosis is unknown, however. Most patients require a definitive chemical or surgical pleurodesis procedure for pneumothorax and chylothorax to prevent recurrences. The optimal procedure and timing of therapy is unknown, however, and the failure rate for pleurodesis is high. The management of pneumothorax and chylothorax in LAM has important consequences for subsequent lung transplantation. The frequency of pneumothorax in LAM and the cohesiveness of the LAM patient community facilitate the study of pleural disease. Properly designed clinical studies are needed to answer important questions in the diagnosis and treatment of pleural complications in LAM.

References

- [1] Kalassian KG, Doyle R, Kao P, et al. Lymphangioliomyomatosis: new insights. *Am J Respir Crit Care Med* 1997;155:1183–6.
- [2] Sullivan EJ. Lymphangioliomyomatosis: a review. *Chest* 1998;114:1689–703.
- [3] Tattersfield AE, Harrison TW. Step 3 of the asthma guidelines. *Thorax* 1999;54:753–4.
- [4] Lutembacher R. Dysembryomes metatypique des reins: carcinose submiliare aigue du poumon avec emphyseme generalise et double pneumothorax. *Ann Med* 1918;5:435–50.
- [5] Castro M, Shepherd CW, Gomez MR, et al. Pulmonary tuberous sclerosis. *Chest* 1995;107:189–95.
- [6] Dwyer JM, Hickie JB, Garvan J. Pulmonary tuberous sclerosis: report of three patients and a review of the literature. *QJM* 1971;40:115–25.
- [7] Hauck RW, Konig G, Permanetter W, et al. Tuberous sclerosis with pulmonary involvement. *Respiration (Herrlisheim)* 1990;57:289–92.
- [8] Uzzo RG, Libby DM, Vaughan Jr ED, Levey SH. Coexisting lymphangioliomyomatosis and bilateral angiomyolipomas in a patient with tuberous sclerosis. *J Urol* 1994;151:1612–5.
- [9] Valensi QJ. Pulmonary lymphangiomyoma, a probable forme frust of tuberous sclerosis: a case report and survey of the literature. *Am Rev Respir Dis* 1973;108:1411–5.
- [10] Cornog Jr JL, Enterline HT. Lymphangiomyoma, a benign lesion of chyloferous lymphatics synonymous with lymphangiopericytoma. *Cancer* 1966;19:1909–30.
- [11] Flume PA. Pneumothorax in cystic fibrosis. *Chest* 2003;123:217–21.
- [12] Mitchell-Heggs PF. Spontaneous pneumothorax in cystic fibrosis. *Thorax* 1970;25:256–7.
- [13] Penketh AR, Knight RK, Hodson ME, Batten JC. Management of pneumothorax in adults with cystic fibrosis. *Thorax* 1982;37:850–3.
- [14] Sahn SA, Heffner JE. Spontaneous pneumothorax. *N Engl J Med* 2000;342:868–74.
- [15] Sassoon CS. The etiology and treatment of spontaneous pneumothorax. *Curr Opin Pulm Med* 1995;1:331–8.
- [16] Yoshida S, Yamagishi T, Fukutake K, et al. [Thoracotomy as treatment for pneumothorax associated with *Pneumocystis carinii* pneumonia in a patient with hemophilia A and the acquired immunodeficiency syndrome]. *Nihon Kyobu Shikkan Gakkai Zasshi* 1995;33:1464–8.
- [17] Chu SC, Horiba K, Usuki J, et al. Comprehensive evaluation of 35 patients with lymphangioliomyomatosis. *Chest* 1999;115:1041–52.
- [18] Corrin B, Liebow AA, Friedman PJ. Pulmonary lymphangiomyomatosis: a review. *Am J Pathol* 1975;79:348–82.
- [19] Oh YM, Mo EK, Jang SH, et al. Pulmonary lymphangioliomyomatosis in Korea. *Thorax* 1999;54:618–21.
- [20] Berkman N, Bloom A, Cohen P, et al. Bilateral spontaneous pneumothorax as the presenting feature in lymphangioliomyomatosis. *Respir Med* 1995;89:381–3.
- [21] Almoosa KF, Ryu J, Mendez J, et al. Management of pneumothorax in lymphangioliomyomatosis: effects on recurrence and lung transplantation complications. *Chest* 2006, in press.
- [22] Johnson SR, Tattersfield AE. Clinical experience of lymphangioliomyomatosis in the UK. *Thorax* 2000;55:1052–7.
- [23] Taylor JR, Ryu J, Colby TV, Raffin TA. Lymphangioliomyomatosis: clinical course in 32 patients. *N Engl J Med* 1990;323:1254–60.
- [24] Urban T, Lazor R, Lacroinque J, et al. Pulmonary lymphangioliomyomatosis: a study of 69 patients. Groupe d'Etudes et de Recherche sur les Maladies "Orphelines" Pulmonaires (GERM"O" P). *Medicine (Baltimore)* 1999;78:321–37.
- [25] Baumann MH, Strange C, Heffner JE, et al. Management of spontaneous pneumothorax: an American College of Chest Physicians Delphi consensus statement. *Chest* 2001;119:590–602.
- [26] Johnson MM. Catamenial pneumothorax and other thoracic manifestations of endometriosis. *Clin Chest Med* 2004;25:311–9.
- [27] Korom S, Canyurt H, Missbach A, et al. Catamenial pneumothorax revisited: clinical approach and systematic review of the literature. *J Thorac Cardiovasc Surg* 2004;128:502–8.
- [28] Peikert T, Gillespie DJ, Cassivi SD. Catamenial pneumothorax. *Mayo Clin Proc* 2005;80:677–80.
- [29] Graf-Deuel E, Knoblauch A. Simultaneous bilateral spontaneous pneumothorax. *Chest* 1994;105:1142–6.

- [30] Sayar A, Turna A, Metin M, et al. Simultaneous bilateral spontaneous pneumothorax report of 12 cases and review of the literature. *Acta Chir Belg* 2004;104:572–6.
- [31] Sunam G, Gok M, Ceran S, Solak H. Bilateral pneumothorax: a retrospective analysis of 40 patients. *Surg Today* 2004;34:817–21.
- [32] Sobonya RE, Quan SF, Fleishman JS. Pulmonary lymphangioliomyomatosis: quantitative analysis of lesions producing airflow limitation. *Hum Pathol* 1985;16:1122–8.
- [33] Carrington CB, Cugell DW, Gaensler EA, et al. Lymphangioliomyomatosis: physiologic-pathologic-radiologic correlations. *Am Rev Respir Dis* 1977;116:977–95.
- [34] Louis H, Los H, Legendijk JH, et al. [Spontaneous pneumothorax in young women: possible lymphangioliomyomatosis]. *Ned Tijdschr Geneesk* 1997;141:1924–8.
- [35] Fukuda Y, Kawamoto M, Yamamoto A, et al. Role of elastic fiber degradation in emphysema-like lesions of pulmonary lymphangiomyomatosis. *Hum Pathol* 1990;21:1252–61.
- [36] Hayashi T, Fleming MV, Stetler-Stevenson WG, et al. Immunohistochemical study of matrix metalloproteinases (MMPs) and their tissue inhibitors (TIMPs) in pulmonary lymphangioliomyomatosis (LAM). *Hum Pathol* 1997;28:1071–8.
- [37] Kitaichi M, Nishimura K, Itoh H, et al. Pulmonary lymphangioliomyomatosis: a report of 46 patients including a clinicopathologic study of prognostic factors. *Am J Respir Crit Care Med* 1995;151(2 Pt 1):527–33.
- [38] Baumann MH, Strange C. Treatment of spontaneous pneumothorax: a more aggressive approach? *Chest* 1997;112:789–804.
- [39] Hatz RA, Kaps MF, Meimarakis G, et al. Long-term results after video-assisted thoracoscopic surgery for first-time and recurrent spontaneous pneumothorax. *Ann Thorac Surg* 2000;70:253–7.
- [40] Massard G, Thomas P, Wihlm JM. Minimally invasive management for first and recurrent pneumothorax. *Ann Thorac Surg* 1998;66:592–9.
- [41] Young LR, Almoosa KF, Pollock-BarZiv S, et al. Patient perspectives on management of pneumothorax in lymphangioliomyomatosis. *Chest* 2006, in press.
- [42] Curtis HJ, Bourke SJ, Dark JH, et al. Lung transplantation outcome in cystic fibrosis patients with previous pneumothorax. *J Heart Lung Transplant* 2005;24:865–9.
- [43] Judson MA, Sahn SA. The pleural space and organ transplantation. *Am J Respir Crit Care Med* 1996;153:1153–65.
- [44] Boehler A, Speich R, Russi EW, et al. Lung transplantation for lymphangioliomyomatosis. *N Engl J Med* 1996;335:1275–80.
- [45] Pechet TT, Meyers BF, Guthrie TJ, et al. Lung transplantation for lymphangioliomyomatosis. *J Heart Lung Transplant* 2004;23:301–8.
- [46] Mortazavi A, Eisenberg MJ, Langleben D, et al. Altitude-related hypoxia: risk assessment and management for passengers on commercial aircraft. *Aviat Space Environ Med* 2003;74:922–7.
- [47] Gendreau MA, DeJohn C. Responding to medical events during commercial airline flights. *N Engl J Med* 2002;346:1067–73.
- [48] Christensen CC, Ryg M, Refvem OK, et al. Development of severe hypoxaemia in chronic obstructive pulmonary disease patients at 2,438 m (8,000 ft) altitude. *Eur Respir J* 2000;15:635–9.
- [49] Cheatham ML, Safcsak K. Air travel following traumatic pneumothorax: when is it safe? *Am Surg* 1999;65:1160–4.
- [50] Flux M, Dille JR. Inflight spontaneous pneumothorax: a case report. *Aerosp Med* 1969;40:660–2.
- [51] Haid MM, Paladini P, Maccherini M, et al. Air transport and the fate of pneumothorax in pleural adhesions. *Thorax* 1992;47:833–4.
- [52] Ho BL. A case report of spontaneous pneumothorax during flight. *Aviat Space Environ Med* 1975;46:840–1.
- [53] Doerr CH, Miller DL, Ryu JH. Chylothorax. *Semin Respir Crit Care Med* 2001;22:617–26.
- [54] Valentine VG, Raffin TA. The management of chylothorax. *Chest* 1992;102:586–91.
- [55] Doerr CH, Allen MS, Nichols III FC, et al. Etiology of chylothorax in 203 patients. *Mayo Clin Proc* 2005;80:867–70.
- [56] Tanaka E, Matsumoto K, Shindo T, et al. Implantation of a pleurovenous shunt for massive chylothorax in a patient with yellow nail syndrome. *Thorax* 2005;60:254–5.
- [57] Valmary J, Delbrouck P, Herning R, et al. [Yellow nail syndrome with chylous effusions]. *Rev Med Interne* 1988;9:425–8.
- [58] Adachi H, Hashimoto T, Komiyama M, et al. [Lymphangioliomyomatosis (LAM) causing chylothorax]. *Nihon Kokyuki Gakkai Zasshi* 2004;42:80–3.
- [59] Bjorn-Hansen L, Larsen KE. [Lymphangioliomyomatosis as the cause of chylothorax]. *Ugeskr Laeger* 1988;150:28–9.
- [60] Buhl L, Larsen KE, Bjorn-Hansen L. Lymphangioliomyomatosis: is fine needle aspiration cytodiagnosis possible? *Acta Cytol* 1988;32:559–62.
- [61] Chuang ML, Tsai YH, Pang LC. Early chylopleurothorax in a patient with pulmonary lymphangioliomyomatosis. *J Formos Med Assoc* 1993;92:278–82.
- [62] Gong JH, Gao L, Zhang LY. [Pulmonary lymphangiomyomatosis: report of a case]. *Zhonghua Nei Ke Za Zhi* 1993;32:313–5.
- [63] Itami M, Teshima S, Asakuma Y, et al. Pulmonary lymphangiomyomatosis diagnosed by effusion cytology: a case report. *Acta Cytol* 1997;41:522–8.
- [64] Kaptanoglu M, Hatipoglu A, Kutluay L, et al. Bilateral chylothorax caused by pleuropulmonary lymphangiomyomatosis: a challenging problem in thoracic surgery. *Scand Cardiovasc J* 2001;35:151–4.

- [65] Morimoto N, Hirasaki S, Kamei T, et al. Pulmonary lymphangiomyomatosis (LAM) developing chylothorax. *Intern Med* 2000;39:738–41.
- [66] Yamauchi M, Nakahara H, Uyama K, et al. Cytologic finding of chyloascites in lymphangiomyomatosis: a case report. *Acta Cytol* 2000;44:1081–4.
- [67] Ryu JH, Moss J, Beck GJ, et al. The NHLBI Lymphangiomyomatosis Registry: characteristics of 230 patients at enrollment. *Am J Respir Crit Care Med* 2006;173(1):105–11.
- [68] Miller WT, Cornog Jr JL, Sullivan MA. Lymphangiomyomatosis: a clinical-roentgenologic-pathologic syndrome. *Am J Roentgenol Radium Ther Nucl Med* 1971;111:565–72.
- [69] Ryu JH, Doerr CH, Fisher SD, et al. Chylothorax in lymphangiomyomatosis. *Chest* 2003;123:623–7.
- [70] Silverstein EF, Ellis K, Wolff M, et al. Pulmonary lymphangiomyomatosis. *Am J Roentgenol Radium Ther Nucl Med* 1974;120:832–50.
- [71] Avila NA, Kelly JA, Chu SC, et al. Lymphangiomyomatosis: abdominopelvic CT and US findings. *Radiology* 2000;216:147–53.
- [72] Pallisa E, Sanz P, Roman A, et al. Lymphangiomyomatosis: pulmonary and abdominal findings with pathologic correlation. *Radiographics* 2002;22(Spec No):S185–98.
- [73] Schneider AR, Jacobi V, Achenbach HJ, Caspary WF. [Lymphangiomyomatosis (LAM): a rare cause of ascites and pleural effusion]. *Dtsch Med Wochenschr* 2004;129:1375–8.
- [74] Merchant RN, Pearson MG, Rankin RN, et al. Computerized tomography in the diagnosis of lymphangiomyomatosis. *Am Rev Respir Dis* 1985;131:295–7.
- [75] Graham ML, Spelsberg TC, Dines DE, et al. Pulmonary lymphangiomyomatosis: with particular reference to steroid-receptor assay studies and pathologic correlation. *Mayo Clin Proc* 1984;59:3–11.
- [76] Kumasaka T, Seyama K, Mitani K, et al. Lymphangiogenesis in lymphangiomyomatosis: its implication in the progression of lymphangiomyomatosis. *Am J Surg Pathol* 2004;28:1007–16.
- [77] Longacre TA, Hendrickson MR, Kapp DS, et al. Lymphangiomyomatosis of the uterus simulating high-stage endometrial stromal sarcoma. *Gynecol Oncol* 1996;63:404–10.
- [78] Matsui K, Tatsuguchi A, Valencia J, et al. Extrapulmonary lymphangiomyomatosis (LAM): clinicopathologic features in 22 cases. *Hum Pathol* 2000;31:1242–8.
- [79] Kumasaka T, Seyama K, Mitani K, et al. Lymphangiogenesis-mediated shedding of LAM cell clusters as a mechanism for dissemination in lymphangiomyomatosis. *Am J Surg Pathol* 2005;29:1356–66.
- [80] Johnson S. Rare diseases. 1. Lymphangiomyomatosis: clinical features, management and basic mechanisms. *Thorax* 1999;54:254–64.
- [81] Teba L, Dedhia HV, Bowen R, et al. Chylothorax review. *Crit Care Med* 1985;13:49–52.
- [82] Thambo JB, Jimenez M, Jougon J, et al. [Diagnostic and therapeutic value of lymphography in persistent postoperative chylothorax]. *Arch Mal Coeur Vaiss* 2004;97:546–8.
- [83] Paes ML, Powell H. Chylothorax: an update. *Br J Hosp Med* 1994;51:482–90.
- [84] Johnstone DW, Feins RH. Chylothorax. *Chest Surg Clin N Am* 1994;4:617–28.
- [85] Hashim SA, Roholt HB, Babayan VK, et al. Treatment of chyluria and chylothorax with medium-chain triglyceride. *N Engl J Med* 1964;270:756–61.
- [86] Jensen GL, Mascioli EA, Meyer LP, et al. Dietary modification of chyle composition in chylothorax. *Gastroenterology* 1989;97:761–5.
- [87] Ramos W, Faintuch J. Nutritional management of thoracic duct fistulas: a comparative study of parenteral versus enteral nutrition. *JPEN J Parenter Enteral Nutr* 1986;10:519–21.
- [88] Sassoon CS, Light RW. Chylothorax and pseudochylothorax. *Clin Chest Med* 1985;6:163–71.
- [89] Hughes E, Hodder RV. Pulmonary lymphangiomyomatosis complicating pregnancy. A case report. *J Reprod Med* 1987;32:553–7.
- [90] Lieberman J, Agliozzo CM. Intrapleural nitrogen mustard for treating chylous effusion of pulmonary lymphangiomyomatosis. *Cancer* 1974;33:1505–11.
- [91] Luna CM, Gene R, Jolly EC, et al. Pulmonary lymphangiomyomatosis associated with tuberous sclerosis: treatment with tamoxifen and tetracycline-pleurodesis. *Chest* 1985;88:473–5.
- [92] Pamukcoglu T. Lymphangiomyoma of the thoracic duct with honeycomb lungs. *Am Rev Respir Dis* 1968;97:295–301.
- [93] Bush JK, McLean RL, Sieker HO. Diffuse lung disease due to lymphangiomyoma. *Am J Med* 1969;46:645–54.
- [94] Johnson SR, Tattersfield AE. Decline in lung function in lymphangiomyomatosis: relation to menopause and progesterone treatment. *Am J Respir Crit Care Med* 1999;160:628–33.
- [95] Rossi GA, Balbi B, Oddera S, et al. Response to treatment with an analog of the luteinizing-hormone-releasing hormone in a patient with pulmonary lymphangiomyomatosis. *Am Rev Respir Dis* 1991;143:174–6.
- [96] Seyama K, Kira S, Takahashi H, et al. Longitudinal follow-up study of 11 patients with pulmonary lymphangiomyomatosis: diverse clinical courses of LAM allow some patients to be treated without anti-hormone therapy. *Respirology* 2001;6:331–40.
- [97] Taveira-DaSilva AM, Stylianou MP, Hedin CJ, et al. Decline in lung function in patients with lymphangiomyomatosis treated with or without progesterone. *Chest* 2004;126:1867–74.
- [98] Al Zubairy SA, Al Jazairi AS. Octreotide as a therapeutic option for management of chylothorax. *Ann Pharmacother* 2003;37:679–82.

- [99] Demos NJ, Kozel J, Scerbo JE. Somatostatin in the treatment of chylothorax. *Chest* 2001;119:964–6.
- [100] Evans J, Clark MF, Mincher L, et al. Chylous effusions complicating lymphoma: a serious event with octreotide as a treatment option. *Hematol Oncol* 2003;21:77–81.
- [101] Gabbieri D, Bavutti L, Zaca F, et al. Conservative treatment of postoperative chylothorax with octreotide. *Ital Heart J* 2004;5:479–82.
- [102] Leelahanon S, Petlek W, Sontimuang W, et al. Can octreotide be the first line treatment for chylothorax? *J Med Assoc Thai* 2003;86(Suppl 3):S741–5.